



Contents lists available at ScienceDirect

## International Journal of Surgery Case Reports

journal homepage: [www.casereports.com](http://www.casereports.com)

# Measurement of blood pressure in a thalidomide-impaired patient who required ovarian cystectomy: A case report

Yuka Shiga<sup>a</sup>, Fumiyo Nojiri<sup>a</sup>, Atsuto Yoshizawa<sup>b</sup>, Takuro Shimbo<sup>c</sup>, Shoji Kawachi<sup>a,\*</sup><sup>a</sup> Department of Anesthesiology, National Center for Global Health and Medicine Hospital, Tokyo, Japan<sup>b</sup> Department of General Internal Medicine, National Center for Global Health and Medicine Hospital, Tokyo, Japan<sup>c</sup> Department of Clinical Study and Informatics, Center for Clinical Sciences, National Center for Global Health and Medicine, Tokyo, Japan

## ARTICLE INFO

## Article history:

Received 29 November 2013

Received in revised form 29 April 2014

Accepted 9 May 2014

Available online 20 May 2014

## Keywords:

Thalidomide

Non-invasive blood pressure measurements

Upper limb defects

## ABSTRACT

**INTRODUCTION:** Thalidomide was available for use over-the-counter between 1958 and 1962, and more than 300 thalidomide-impaired people have been confirmed in Japan. Currently, thalidomide-impaired people are nearing the age of 50 years and sometimes require medical treatment or surgery. However, a sphygmomanometer cannot be used to measure the blood pressure in some thalidomide-impaired people because of upper-limb shortening or hypoplastic defects. We encountered a patient with thalidomide-related upper limb defects who required abdominal ovarian cystectomy.

**PRESENTATION OF CASE:** The patient was a 49-year-old woman (146.5 cm, 35.9 kg) with thalidomide-related upper-limb defects, but no dysplasia of the lower limbs, who underwent abdominal ovarian cystectomy. During the surgery, the patient's arterial blood pressure was monitored in her lower limbs by both non-invasive and invasive methods, and almost the same variations of the blood pressure between the invasive and non-invasive measurements were observed.

**DISCUSSION:** Usually, blood pressure measurements are performed in a non-invasive manner in the upper limbs, however, such measurement could not be performed in the present case. There are few reports of measurement of the blood pressure or surgery under anaesthesia in thalidomide-impaired patients, and we report here that it was useful to measure the blood pressure in the lower limbs in the current patient. Invasive arterial pressure measurements showed almost the same changes as the non-invasive pressure measurements, although the systolic blood pressure was 10–20 mmHg lower than the noninvasively measured systolic blood pressure.

**CONCLUSION:** Non-invasive blood pressure measurements in the lower limbs might be useful in thalidomide-impaired patients requiring blood pressure monitoring, but further studies are required to validate this method.

© 2014 The Authors. Published by Elsevier Ltd. on behalf of Surgical Associates Ltd. This is an open access article under the CC BY-NC-ND license (<http://creativecommons.org/licenses/by-nc-nd/3.0/>).

## 1. Introduction

Thalidomide-impaired people are now approaching the age of 50 years, and the likelihood of their consulting a hospital for the treatment of various diseases or surgery is expected to increase. However, because of limb defects or shortening, a conventional blood pressure cuff cannot be used around the upper or lower extremities. Thus, blood pressure can be difficult to measure in a non-invasive manner in a general ward or outpatient setting.

\* Corresponding author at: Department of Anesthesiology, National Center for Global Health and Medicine Hospital, Toyama 1-21-1, Shinjuku-ku, Tokyo 162-8655, Japan. Tel.: +81 33 202 7181; fax: +81 33 207 1038.

E-mail addresses: [yshiga.chiba.u@gmail.com](mailto:yshiga.chiba.u@gmail.com) (Y. Shiga), [bass5fumiyo-n@ybb.ne.jp](mailto:bass5fumiyo-n@ybb.ne.jp) (F. Nojiri), [ayoshiza@hosp.ncgm.go.jp](mailto:ayoshiza@hosp.ncgm.go.jp) (A. Yoshizawa), [tschimbo@hosp.ncgm.go.jp](mailto:tschimbo@hosp.ncgm.go.jp) (T. Shimbo), [skawachi@niid.go.jp](mailto:skawachi@niid.go.jp) (S. Kawachi).

<http://dx.doi.org/10.1016/j.ijscr.2014.05.002>

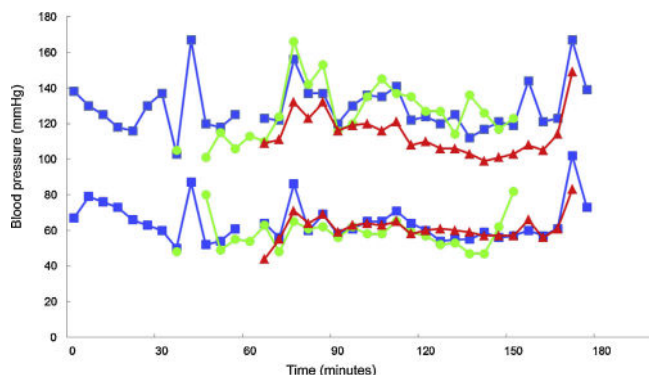
2210-2612/© 2014 The Authors. Published by Elsevier Ltd. on behalf of Surgical Associates Ltd. This is an open access article under the CC BY-NC-ND license (<http://creativecommons.org/licenses/by-nc-nd/3.0/>).

Herein, we present the case of a patient with thalidomide-related upper limb defects who required an ovarian cystectomy.

## 2. Presentation of case

The patient was a 49-year-old woman (146.5 cm, 35.9 kg) with a past medical history of undergoing right nephrectomy at the age of 6 years, and torsion of the ovarian cyst pedicle at the age of 18 years (details unknown). She had upper-limb defects, but no dysplasia of the lower limbs; she was nearly independent in her daily home activities. Because of the near-absence of her upper limbs, a conventional sphygmomanometer could not be used to measure the blood pressure of the patient. However, her blood pressure could be measured in the lower legs using a cuff and sphygmomanometer.

She was diagnosed during a medical examination as having an ovarian cyst measuring 50 mm in diameter. Therefore, abdominal ovarian cystectomy was scheduled, and surgery under general anaesthesia combined with epidural anaesthesia was planned. The



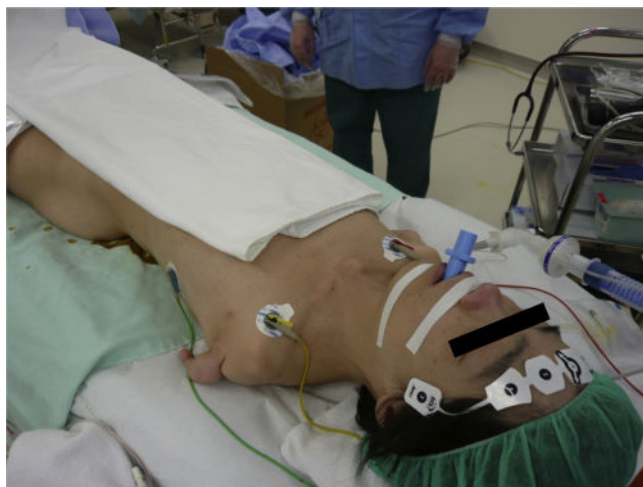**Fig. 1.** Blood pressure measurements obtained in a non-invasive manner using a Nihon Kohden device (—■—) or Terumo device (—●—), or invasively using a Nihon Kohden device (—▲—).

patient's vital signs and other systemic parameters, including the pulse, blood pressure and arterial oxygen saturation were monitored by electrocardiography, non-invasive sphygmomanometry, invasive arterial pressure measurements, pulse oximetry and neuromuscular block monitoring.

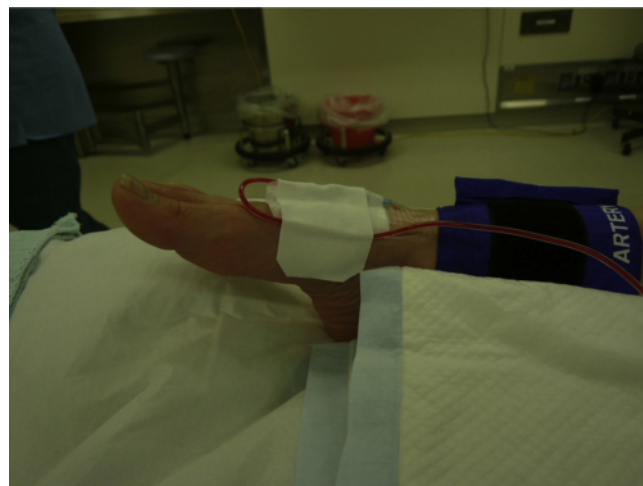No pre-medication was given. After transfer to the operating room, a peripheral intravenous line was inserted into the dorsal vein on the left side. During the surgery, blood pressure measurements were obtained at 5-min intervals using the cuff of the anaesthesia machine (10-cm cuff for paediatric use, fitting a circumference of 15–23 cm, YP-962T; Nihon Kohden, Co., Tokyo, Japan) around the right lower leg, and the cuff of a conventional blood pressure measurement device intended for home use (13-cm cuff for small adults, fitting a circumference of 17–26 cm, model H55; Terumo, Tokyo, Japan) around the left lower leg. Invasive arterial pressure measurements were measured in the dorsal artery of the right foot. The results are shown in Figs. 1–3.

An epidural catheter was inserted at the L1/2 level using an 18-gauge Tuohy needle. The depth of the epidural space was 2.5 cm from the skin. The catheter was fixed at 9 cm from the tip.

After induction of anaesthesia using propofol (60 mg), fentanyl (0.1 mg), and rocuronium (20 mg), tracheal intubation was performed. The intubation was relatively easy, and the Cormack–Lehane grade was 1. During anaesthesia induction, the



**Fig. 2.** The patient had upper-limb defects, and the vital signs and other systemic parameters were monitored by electrocardiography, non-invasive sphygmomanometry, invasive arterial pressure measurements, pulse oximetry and neuromuscular block monitoring throughout the procedure.



**Fig. 3.** The patient had upper-limb defects, and the vital signs and other systemic parameters were monitored by electrocardiography, non-invasive sphygmomanometry, invasive arterial pressure measurements, pulse oximetry and neuromuscular block monitoring throughout the procedure.

patient's heart rate was 70–80 beats per minute, and blood pressure was 120/60 mmHg as measured using the Nihon Kohden device and 110/50 mmHg as measured using the Terumo device. Both the blood pressure values remained almost constant, with little variations. The invasively measured blood pressure was 100/50 mmHg, the systolic blood pressure being 10–20 mmHg lower and diastolic blood pressure being 10 mmHg lower than the noninvasively measured blood pressure. The anaesthesia was maintained with sevoflurane and ropivacaine. The patient's cardiovascular and respiratory status remained stable throughout the procedure. The operating time was 1 h and 17 min, and the anaesthesia time was 2 h and 35 min. The postoperative course was uneventful.

### 3. Discussion

According to the monitoring guidelines of the American Society of Anesthesiologists, blood pressure should be measured every 5 min during surgery.<sup>1</sup> Usually, blood pressure measurements are performed in a non-invasive manner in the upper limbs, but such measurement could not be performed in our patient reported here because of upper limb defects related to thalidomide. There are few reports of measurement of the blood pressure or surgery under anaesthesia in thalidomide-impaired patients, and we report here that it was useful to measure the blood pressure in the lower limbs in the current patient.<sup>2,3</sup> Although use of invasive arterial pressure measurements in the femoral artery or superficial temporal artery have been reported, invasive monitoring itself can be problematic because arterial cannulation is infrequently involved in complications such as bleeding, thrombosis and infection.<sup>4,5</sup>

Non-invasive blood pressure measurement methods used in clinical practice include the auscultatory, oscillometric, and tonometric methods. Among these, automated sphygmomanometers which measure blood pressure based on the principles of oscillometry and tonometry are often used in the home as well as in hospitals. In the oscillometric method, the arterial wall vibrates as the cuff pressure decreases between the highest and lowest blood pressures. The blood pressure is recognized from the changes in the vibrations detected by a pressure sensor. Automated sphygmomanometers use different types of algorithms. The oscillometric method can be used to measure the blood pressure anywhere in the body, since it depends not on the sound, but on the waveform pattern of the arterial pulsation and can be distinguished from noise.<sup>6</sup> Therefore, this method can be used to measure the blood pressure

in children with feeble Korotkov's sounds or patients in a shock state or noisy surroundings. Furthermore, the method is easy and non-invasive, and inter-operator differences are minimal. In the present case, the oscillometric method was used to measure the blood pressure using sphygmomanometers with cuffs fitting the circumferences of the lower extremities. In this case, we placed the cuff at the ankle because the size of small or adult cuff was often appropriate for the ankle. The sites for blood pressure measurement of the lower limbs were at the calf and the ankle. It was reported that the blood pressure either at the calf or at the ankle tends to be higher than that at the arm, and the measurements at the ankle were associated with less discomfort than those at the calf.<sup>2</sup>

Invasive arterial pressure measurements require insertion and placement of a catheter into the artery, connecting the catheter to an external transducer, and the blood pressure is measured directly from the pressure waveform. Possible puncture sites include the radial, ulnar, brachial, axillary, femoral, and dorsalis pedis arteries. In this method, the systolic blood pressure increases and the mean blood pressure decreases slightly as the distance between the puncture site and the heart increases.<sup>5</sup> In the present case, the invasive arterial pressure measurements showed almost the same changes as the non-invasive pressure measurements, although the invasively measured systolic blood pressure was 10–20 mmHg lower than the systolic pressure measured in a non-invasive manner. This difference was thought to arise from the difference in the measurement methods.

The blood pressure monitoring of patients with limb defects or shortening varies with the severity of the limb defects. It is better to check the arteries and veins by the ultrasonic echo or computed tomography angiography beforehand. Furthermore, it is preferred to cannulate vessels with checking by the ultrasonic echo. In the present case, the patient had normal lower limbs, femoral arteries, and veins. Therefore, the blood pressure could be measured at the lower limbs. However, some reports have described patients with limb defects or shortening may also have an abnormal vasculature or hypoplasia.<sup>4</sup> The measurement of blood pressure in these cases might be difficult.

#### 4. Conclusion

The present case of a thalidomide-impaired patient with upper limb defects undergoing ovarian cystectomy under general and epidural anaesthesia could be managed without event. It is difficult to measure the blood pressure in many thalidomide-impaired patients. Non-invasive blood pressure measurements in the lower limbs might be useful in the case of a thalidomide-impaired patient

with upper limb defects, but further studies are required to validate this method.

#### Conflict of interest

All authors have no conflicts of interest.

#### Funding

This study was funded by a Grant-in-Aid for Research on Regulatory Science of Pharmaceuticals and Medical Devices from the Ministry of Health, Labour and Welfare, Japan, and the Health and Labour Sciences Research Grants for Research on Emerging and Re-emerging Infectious Diseases (H22 Shinko-Ippan-014) from the Ministry of Health, Labour and Welfare, Japan.

#### Ethical approval

Written informed consent was obtained from the patient for publication of this case report and any accompanying images. A copy of the written consent is available for review by the Editor-in-Chief of this journal.

#### Author contributions

Yuka Shiga was the principal author and major contributor to writing the manuscript. Fumiyo Nojiri analysed and interpreted the patient data and reviewed the literature. Atsuto Yoshizawa and Takuro Shimbo read and corrected the manuscript. Shoji Kawachi was in charge of the manuscript supervision and is the corresponding author. All have authors read and approved submission of the final manuscript.

#### References

1. American Society of Anesthesiologists. *Standards for basic anesthetic monitoring*; 2005 <http://www.asahq.org/publicationsAndServices/standards/02.pdf> [accessed 05.05.08].
2. Moore C, Dobson A, Kinagi M, Dillon B. Comparison of blood pressure measured at the arm, ankle and calf. *Anaesthesia* 2008;**63**:1327–31.
3. McCrory JW. Anaesthesia and thalidomide-related abnormalities. *Anaesthesia* 1988;**43**:613–4.
4. Ohtsuka T, Kato E, Takatsuki A. Anesthetic management of a patient with tetra-amelia. *Masui* 2003;**52**:650–1.
5. Schrieder AB, Barbeito A, Bar-Yosef S, Mark JB. Cardiovascular monitoring. In: Miller RD, editor. *Miller's anaesthesia*. 7th ed. Philadelphia, PA: Churchill Livingstone; 2009. p. 1267–328.
6. Geake WB, Amore JN, Scott DH. An automated system for the functional evaluation of oscillometric noninvasive blood pressure monitors. *J Med Eng Technol* 1995;**19**:162–76.

#### Open Access

This article is published Open Access at [scimedirect.com](http://scimedirect.com). It is distributed under the [IJSCR Supplemental terms and conditions](#), which permits unrestricted non commercial use, distribution, and reproduction in any medium, provided the original authors and source are credited.