

# THALIDOMIDE EMBRYOPATHY AND LIMB DEFECTS

## EXPERIENCES IN HABILITATION OF CHILDREN WITH ECTROMELIAS\*

BY

WOLFGANG A. MAIER

*From Universität Kinderklinik, München, Germany*

Abnormalities of limbs have been seen occasionally at all times. Thalidomide-embryopathy, however, has produced special types of defects of the extremities, which in variety and above all in numbers has made necessary the provision of special centres for treatment.

At the Dept. of Paediatric Surgery and Orthopaedics of the University Children's Hospital, München, we observed from January 1959 to December 1963 approximately 141 children with severe limb deformities, of which 135 children were diagnosed as the 'dysmelia syndrome' as defined by Wiedemann (1961), Lenz (1961), McBride (1961), Weicker and others (1962).

Retrospectively 79% of the mothers were certain they had taken thalidomide during the critical phase of pregnancy, that is between the 32nd and the 50th day after the first day of the last menstruation. With another 16% we found that either thalidomide had been in the house or had been used by a member of the family, or that the mother had taken analgesic, hypnotic, or sedative drugs during the critical time. In only 5% of the mothers could we discover no reason for the abnormalities.

Exactly 8 months after the voluntary withdrawal of all thalidomide-containing drugs by the firm concerned the wave of dysmelia cases suddenly retreated.

During the following 16 months only 3 newborn babies with extremity defects were seen at the hospital, and these could all be distinguished from the dysmelia syndrome.

In 1960 at this hospital we made our first efforts to treat dysmelic children. A treatment centre has now been established, working as an outpatient clinic for limb deformities.

The cases are divided up as shown in the Table.

The Dysmelia Centre was intentionally separated from the general hospital and was installed in an

apartment nearby. From the beginning the infants were not to have the feeling that they were ill and had to come for treatment. In the neutral surroundings of a normal house they feel themselves more at home and soon regard the therapy as an ordinary part of their day. Physiotherapists and occupational therapist work in separate rooms. A psychologist has proved especially useful and is an important help in adapting the handicapped child to the use of technical aids, as well as in assisting the parents in educating their children. The parents leave their children at the centre, according to a time-table. If necessary, they themselves attend in order to go on with the exercises at home. The regular contact with the parents provides a good opportunity for influencing the home situation and therefore of preventing the child with limb defects from becoming spoilt by a misguided love and helpfulness. Unfortunately we also meet with the contrary; it is equally wrong for parents to try with exaggerated perseverance to get a highly differentiated skill out of their dysmelic children and to ask too much of them.

Apart from the traditional methods of examination, we make certain special inquiries, which need be mentioned only briefly.

With the aid of a modern constant current impulse apparatus we test the excitability of the muscles.

Arteriograms showed that even in those children with the severest deformities, i.e. with very short ectromelias of the axial type and with one-finger phocomelias, the regular topography and division of

TABLE

Deformity	No. of Cases
Bilateral amelia	2
Unilateral amelia with phocomelia at the opposite side	6
Unilateral amelia with phocomelia of the 3 remaining limbs	1
Bilateral one-finger phocomelia	2
Tetra-ectromelia	20
Bilateral ectromelia (axial type)	36
Bilateral ectromelia (combined type, axial with distal)	6
Bilateral ectromelia (only distal type)	35
Malformations of the thumb	27

\* A paper read at a meeting of the British Association of Paediatric Surgeons in Rotterdam, September 1964.

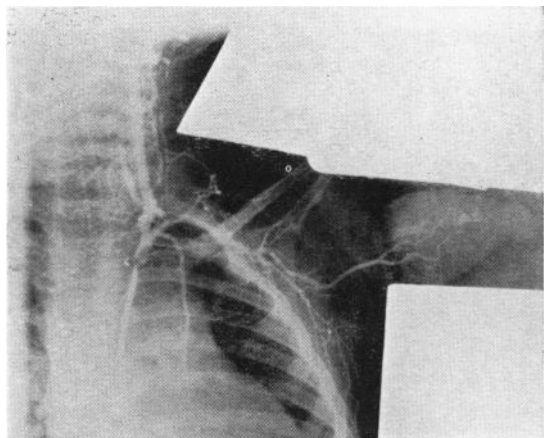


FIG. 1.—Arteriogram of a 2½-year-old boy with one-finger phocomelia.

the brachial artery and its branches was only reduced in proportion to the entire length of the arm. Even with one-finger phocomelias the arterial system is still normally developed, so that regular division of the brachial artery into radial and ulnar can be observed (Fig. 1). All existing fingers are supplied by the ulnar artery: the radial artery does not extend beyond the wrist (Fig. 2).

The picture of the venous system revealed by venography is different. It is characterized by the frequent hypoplasia or anomaly of the cephalic vein; for instance its division into three branches, the first of which joins the brachial vein (Fig. 3), or its direct junction with the jugular vein.

Such considerations are not without importance later on, in attempting operation at the shoulder in order to correct the frequent subluxation, and at the wrist to correct the radial deviation. For the therapy of ectromelic lower extremities (Fig. 4) the early correction of the club-foot which otherwise resists treatment has shown good results. We operate according to the method of Blauth (1963); the fibula is shortened by an osteotomy, and the distal

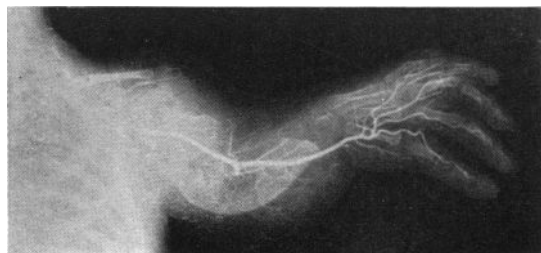


FIG. 2.—Arteriogram of a 3-year-old boy. All fingers are supplied by the ulnar artery.

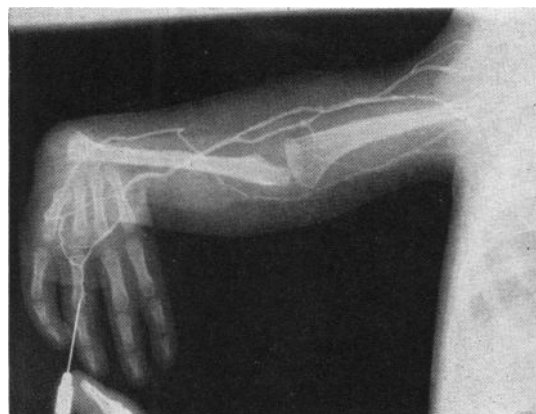

FIG. 3.—Venography of a 3-year-old girl. The cephalic vein divides into three branches.

end of the fibula is put on to the talus. In this way it will be easier later on to apply technical aids (Fig. 5a and b).

Surgery of the upper extremities during early infancy ought to be approached with the utmost caution. Children with bilateral amelia, one-finger phocomelia, and very short ectromelias of the axial type receive their first pneumatic prosthesis at the age of 18 months.

The main interest goes to the amelias, one-finger phocomelias, and severe ectromelias, of which, up to now, 17 patients have been fitted with powered prostheses of the Heidelberg type. Liquid carbon dioxide serves as a source of energy and is stored in a steel bottle. By means of this prostheses we can either move 'pat-hands' or a children's hook. For bilateral amelia and phocomelia we at first constructed 'pat-hands' (Fig. 6). With these only a

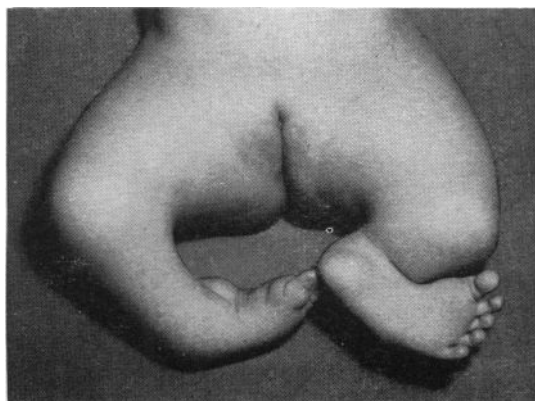
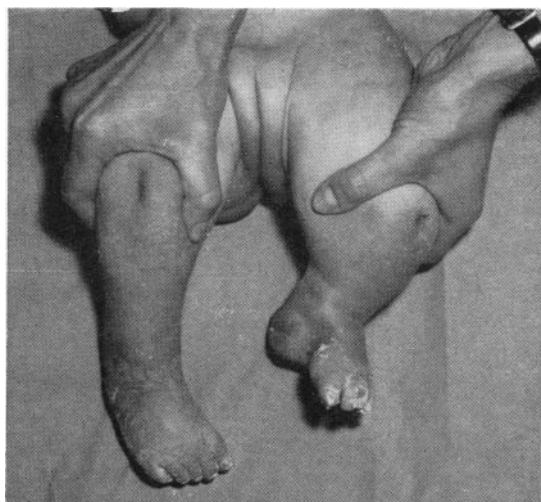
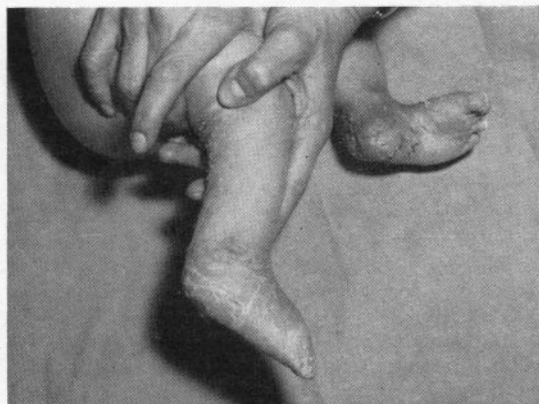


FIG. 4.—Lower extremity ectromelia before treatment.



(a)



(b)

FIG. 5a and b.—The same child shown in Fig. 4 after operation.

movement in the form of a sickle is possible, through an adduction of the artificial forearms. One year later the babies have received powered hook prostheses instead of the 'pat-hand'. Short ectromelias were fitted with a hook from the beginning.

By the third year of life the children are skilled enough to perform correctly a turning movement of the hand like a pronation-supination (Fig. 7). This is effected either by additional key valves for the

finger in the case of ectromelias, or for the chin with amelias (Fig. 8).

The children get used very quickly to the prostheses, with the assistance of an occupational therapist and a physiotherapist. They are obviously happy when able to play, and they resist when the prostheses have to be taken off for a while.

If they manage to reach their mouths with their short arms or to cross them over the breast, the fitting of technical aids can be delayed. All other deformities need training and guidance (Fig. 9 and 10).

In a centre for treatment of limb-deficient children

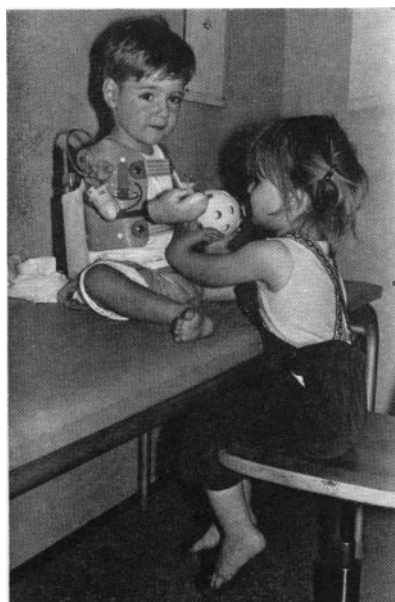


FIG. 6.—Pneumatic pat-hands.

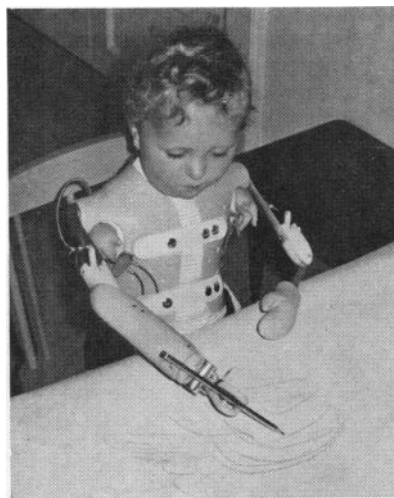

FIG. 7.—Pat-hands and a children's hook on the right with turning movement like pro- and supination.

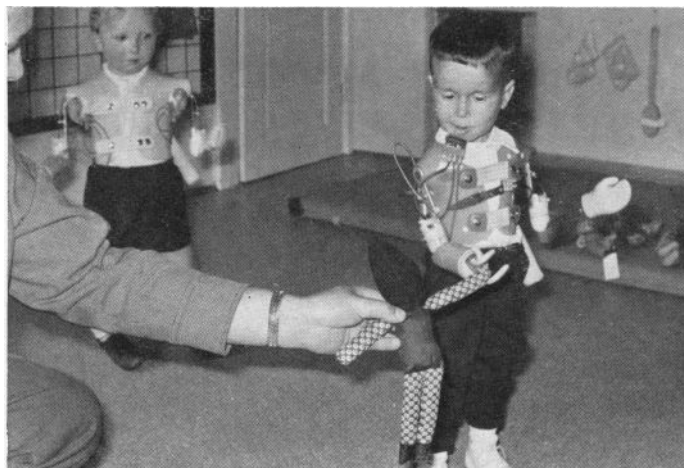

FIG. 8.—A key valve for the chin with bilateral amelia.

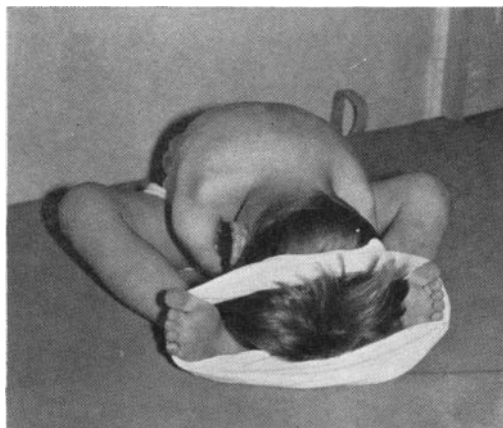

FIG. 9.—The daily training: a child with short ectromelic arms is learning to dress himself.

all those taking part, the physician, the orthopaedic mechanic, the physiotherapist, the occupational therapist, the psychologist, and the teacher have to work together closely. We plan to habilitate the children as effectively as possible for a normal life. How far we succeed will be apparent in the years to come when the first victims of thalidomide-embryopathy are admitted to regular schools.

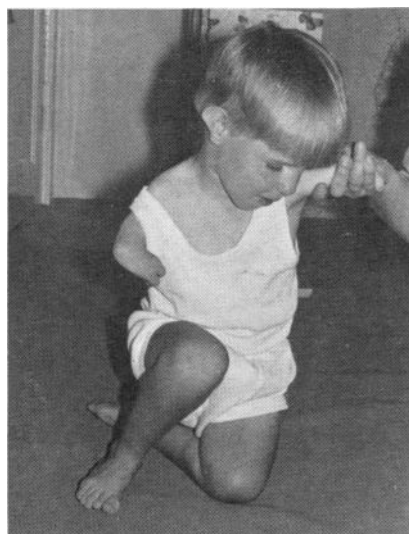


FIG. 10.—Physiotherapist gives instructions to a boy with ectromelic arms to get up without losing his balance.

#### BIBLIOGRAPHY

- Blauth, W. (1963). Beitrag zur operativen Behandlung schwerer Mißbildungen der Unterschenkelknochen. *Arch. orthop. Unfall-Chir.*, 55, 345.
- , and Willert, H. G. (1963). Klinik und Therapie ektromeler Mißbildungen der unteren Extremität. *ibid.*, 55, 521.
- Lenz, W. (1961). Discussion at the Congress of the 'Rheinisch-Westfälische Kinderärzte-Vereinigung' Düsseldorf, Germany, 19.11.1961.
- (1963). Das Thalidomid-Syndrom. *Fortschr. Med.*, 81, 148.
- , and Knapp, K. (1962). Die Thalidomid-Embryopathie. *Dtsch. med. Wschr.*, 87, 1232.
- Maier, W. (1963a). Early treatment of dysmelia. *Germ. med. Mth.*, 8, 45. Shortened translation of the article in the *Dtsch. med. Wschr.*, 88, 69.
- (1963b). Die Thalidomid-Embryopathie aus kinderchirurgischer Sicht. Bisherige Ergebnisse mit einer frühzeitigen prothetischen Versorgung. *Zbl. Chir.*, 88, 1551.
- (1964). Thalidomid-Embryopathie und Gliedmassenfehlbildungen. Erfahrungen bei der Versorgung von Kindern mit Ektromelien. *Bayer. Ärztebl.*, 19, 201.
- McBride, W. G. (1961). Thalidomide and congenital abnormalities. *Lancet*, 2, 1358.
- Weicker, H., Bachmann, K. D., Pfeiffer, R. A., and Gleiss, J. (1962). Thalidomid-Embryopathie. II. Ergebnisse individueller anamnestischer Erhebungen in den Einzugsgebieten der Universitäts-Kinderkliniken Bonn, Köln, Münster und Düsseldorf. *Dtsch. med. Wschr.*, 87, 1597.
- , and Hungerland, H. (1962). Thalidomid-Embryopathie. I. Vorkommen inner- und außerhalb Deutschlands. *ibid.*, 87, 992.
- Wiedemann, H. R. (1961). Hinweis auf eine derzeitige Häufung hypo- und aplastischer Fehlbildungen der Gliedmaßen. *Med. Welt (Stuttg.)*, 37, 1863.